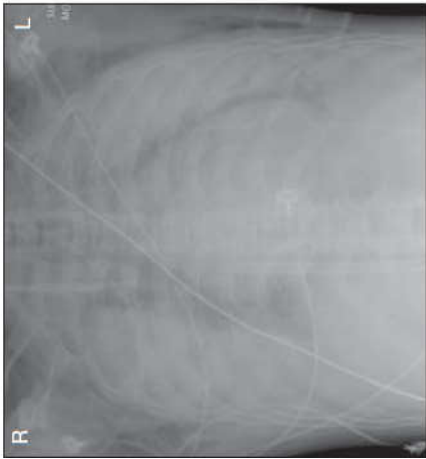


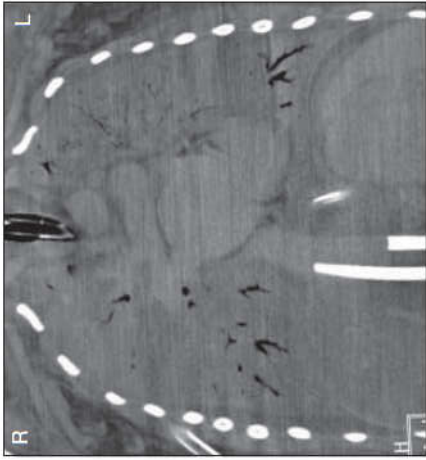
ECMO a respirační selhání

Figure 3. Chest Radiograph and Computed Tomogram of 2 Patients Successfully Treated With ECMO for Confirmed 2009 Influenza A(H1N1)

Chest radiograph

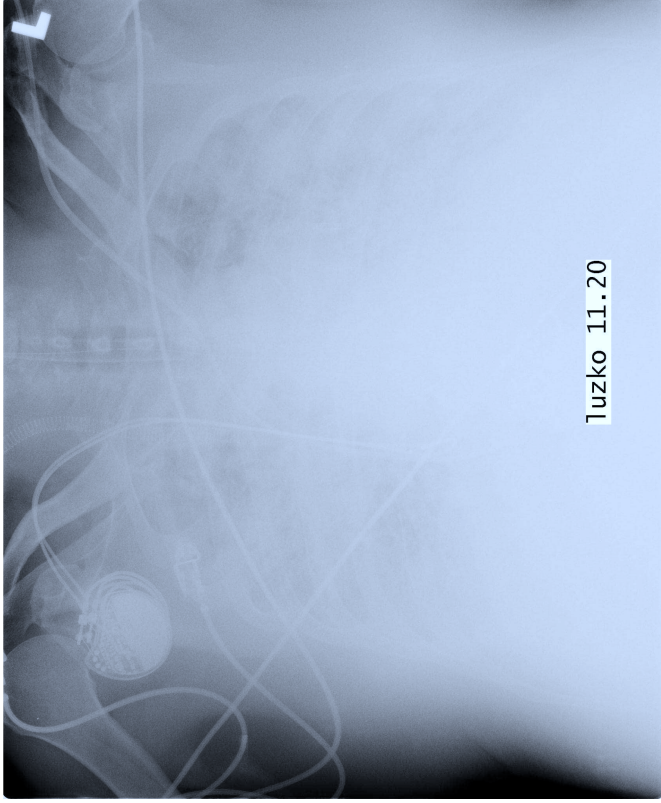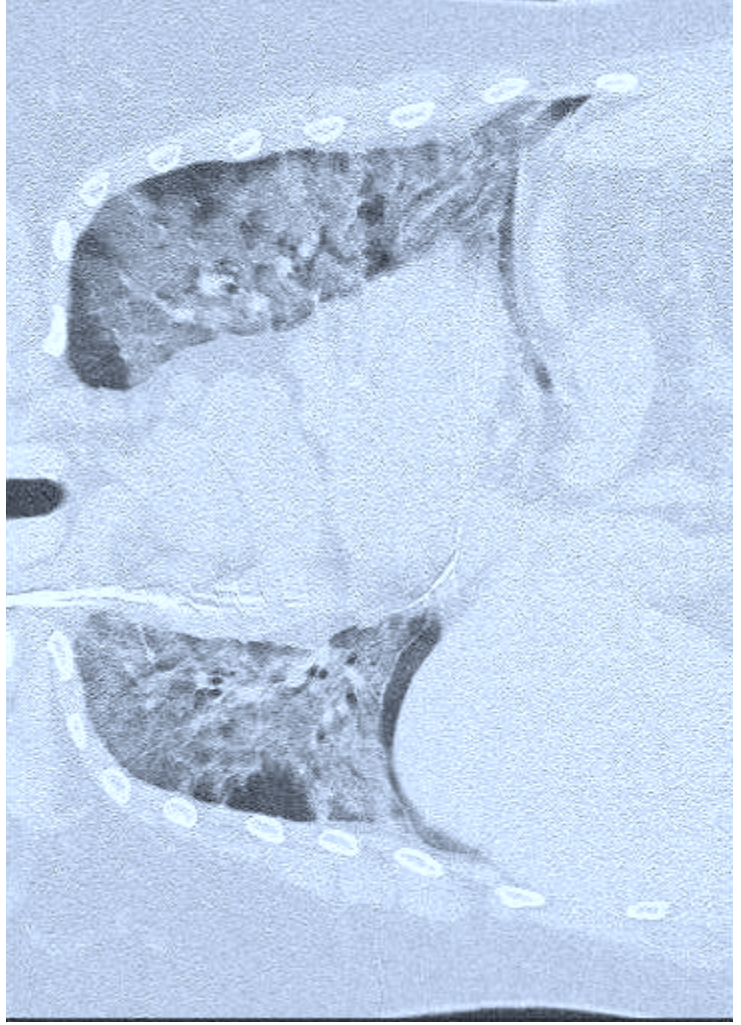
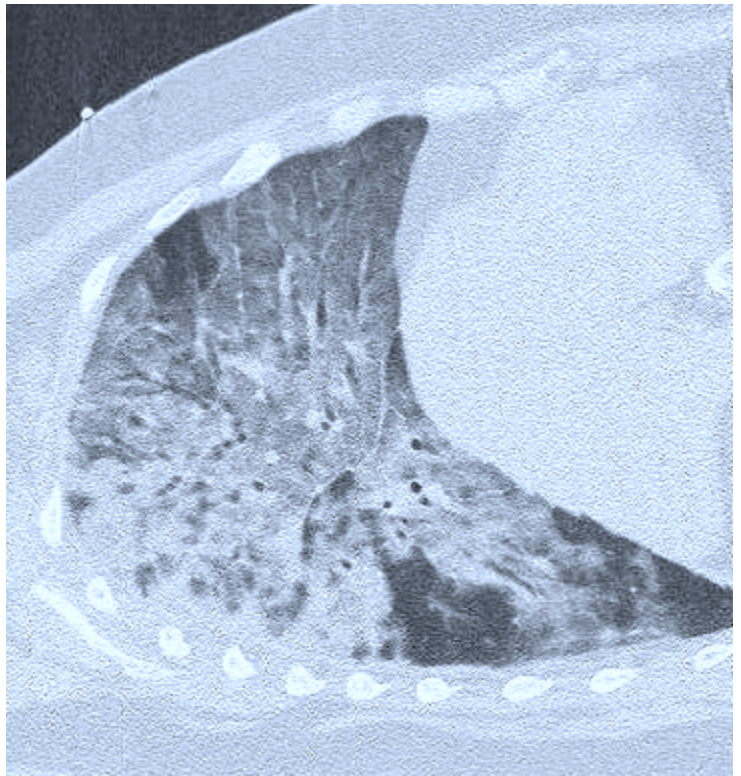


Computed tomogram

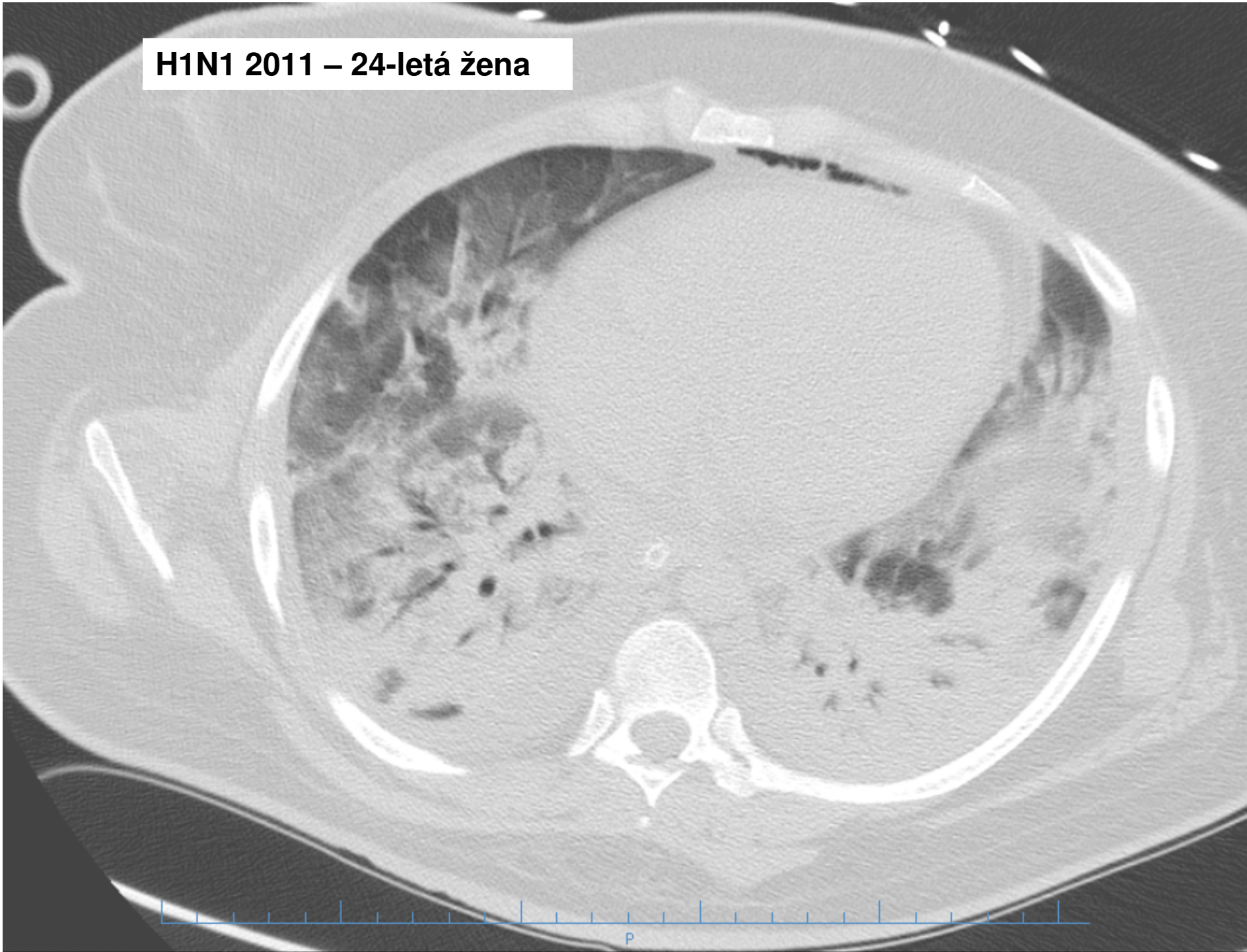


11.20

ECMO indicates extracorporeal membrane oxygenation. The images demonstrate severe bilateral airspace disease with massive loss of normal aerated lung tissue.



H1N1 2011 – 24-letá žena



H1N1 u 6 měsíční holčičky

14. den na V-V ECMO

